

Radio Surgical Treatments with the radioSURG® 2200

Performed at the MVZ of the Paracelsus Hospital Karlsruhe, Germany

Chief Physician J. H. Reus, MD

Medical Specialist for Plastic and Esthetic Surgery

The Cases

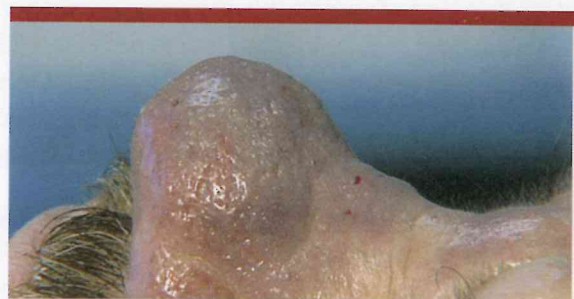- 1. Removal of a Rhinophyma***
- 2. Basalioma at the Nasal Bridge***
- 3. Removal of Xanthelasma, Hemangioma
and Hair Growth perimammillary***
- 4. Traumatic Rupture of the Septum Orbitale in Ferio***
- 5. Removal of pigmented papillomatous
Nevus Cell Nevi at the Neck***
- 6. Anti-Aging-Treatment with the RF-ReFacing® Method***

1. Removal of a Rhinophyma

Case Report

The 55 year old patient had suffered for a longer time from a rhinophyma. Before taking on a new job he thus, wanted it to be removed.

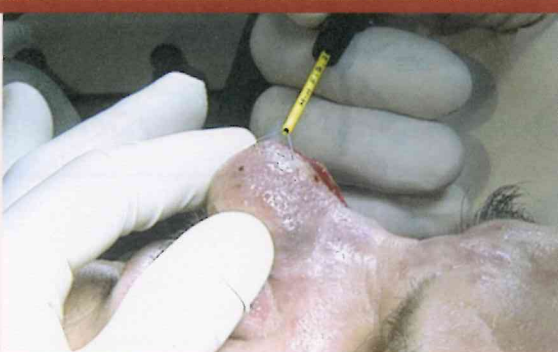After an infraorbital conduction anaesthesia and regional block anaesthesia with Xylocain 2% 1:200 000 at the root of the nose and the nose bridge, the surgery area and the complete face are cleaned with Octenisept, a mucosa antiseptic agent.



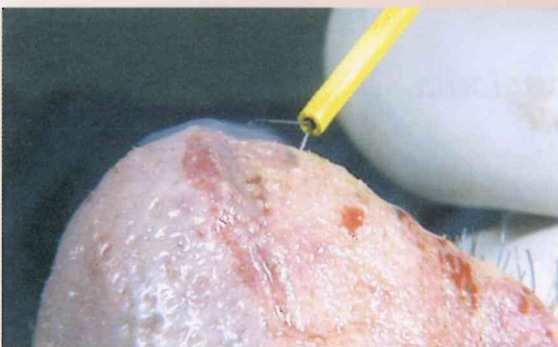
Status preoperative

The Surgical Procedure

With the triangle electrode No. 26 and unit setting CUT 35 watt the basic shape of the nose is reconstructed. To increase the conductivity of the radio waves, the skin is moistened with a wet swab, before it is touched with the activated electrode. This procedure is necessary at the skin surface only.



With the triangle electrode the tissue can be removed evenly, without creating any deep curves.



One half of the nose is almost completely prepared.

The removed tissue, which remains at the electrode wire, is wiped off with a swab. The electrode has to be clean during the complete surgery.

Subsequently further skin layers are removed with the setting CUT/COAG, 35 watt, coagulation degree c3. Due to the chosen coagulation degree, noticeable less bleeding occurs, without leading to burns or necroses. This is an advantage of radio surgery, as the development of heat at the electrode is minor.

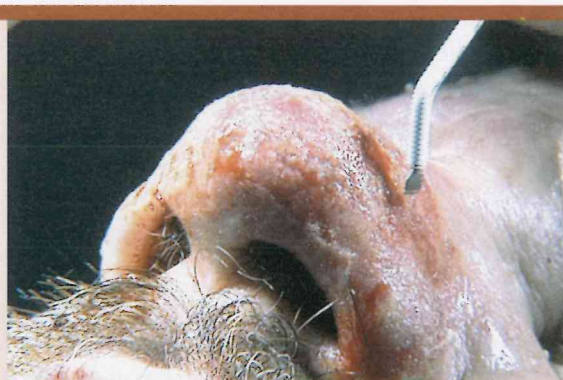To obtain an anatomic comparison, at first only one half of the nose gets prepared, and the tissue is removed layer by layer. With a particularly big rhinophyma it might be of advantage to have a look at a picture of the patient prior to the affection, to design the nose according to the original shape.

The triangle electrode is more suitable for this kind of preparation than a loop electrode as no deep curves will be prepared, and furthermore, it is easier to reach and form the contour of the wing of the nose with the edges of the wire.

A swab moistened with Suprarenin is applied. This compound narrows the vessels leading to hemostasis. The refining is performed with the triangle electrode No. 26. Due to the reason that very fine layers of 0.2 mm can be removed, this electrode, in connection with radio surgery, is especially suitable for this kind of surgery and for the precise design of the shape of the nose.

With this kind of surgery it is always advisable not to set the coagulation degree too high in order to keep the heat development as low as possible. With radio surgery, working in the Megahertz range, it is possible to perform surgeries with significant less heat development compared to conventional high frequency units working in the Kilohertz range. Therefore, it is also possible to work near cartilage and bones without causing necroses. For hemostasis again a swab moistened with Suprarenin is applied.

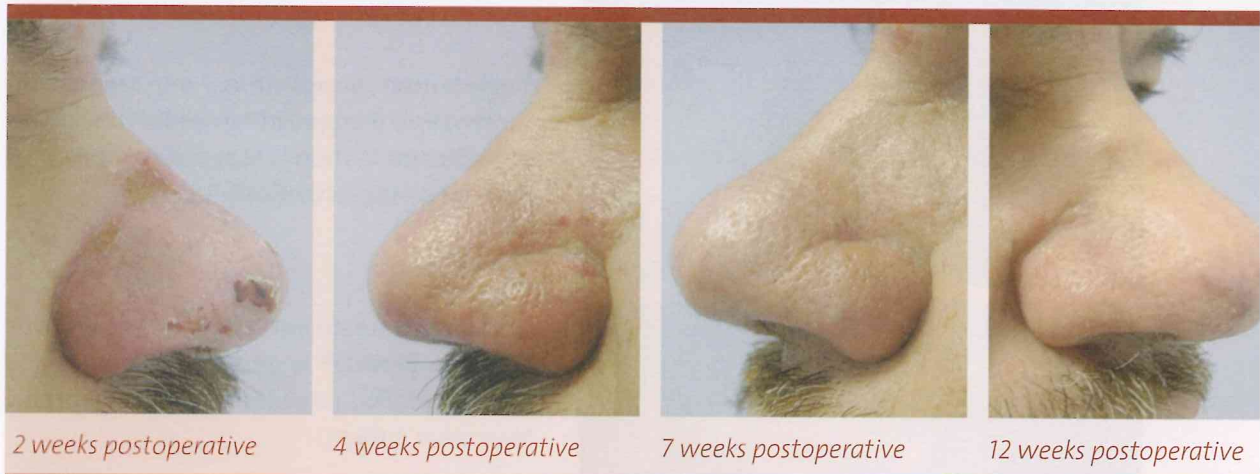With the disc electrode No. 80, setting COAG 12 watt, coagulation degree c4, the nose surface is carefully adapted once again. The edges get broken, smoothed and the transitions are carefully adjusted to give the nose an even skin appearance after the healing process.



As the tissue of the nose is already tightened a bit due to the coagulation, the tip and wings of the nose are outlined from proximal to distal in the final step.

Again a swab moistened with Suprarenin is applied followed by a generous application of Volon A cortisone ointment and covered with Urgotül, an elastic, coated gaze that will not adhere to the wound. With this, additionally a scar prophylaxis is achieved and the generation of keloid is mostly prevented. The dressing remains for 4–5 days.

Status Postoperative



The healing proceeded without problems. The patient was very satisfied with the result.

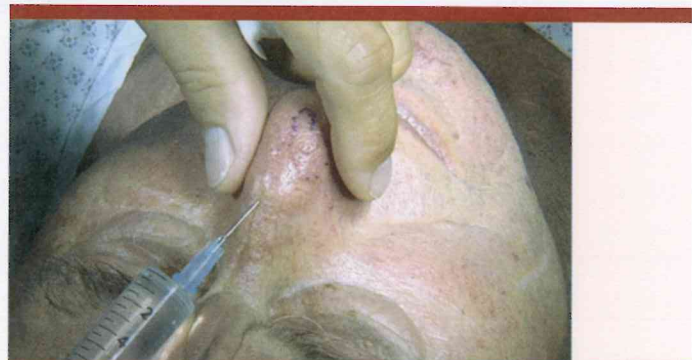2. Basalioma at the Nasal Bridge

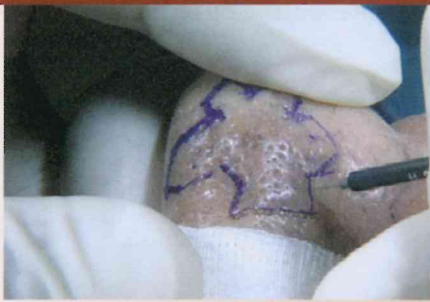Case Report

A 77 year old patient had to get a basalioma on the bridge of the nose removed. Even though the patient was still on Marcumar and no displacement was made it was planned to remove the Basalioma with radio surgery.

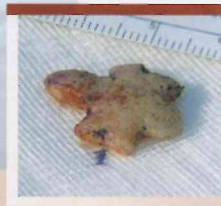Surgical Procedure

After local anaesthesia with Xylocain 2% 1:200 000 on the bridge of the nose and disinfection of the face, the surgical lines were drawn. The plan is to cut the basalioma via little Z-plasties.

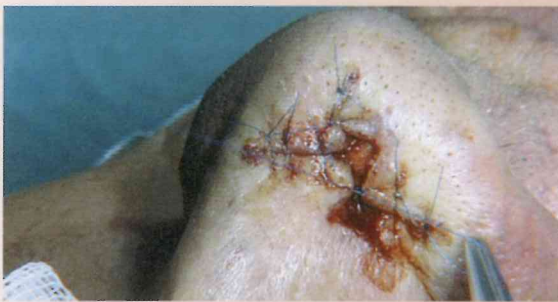



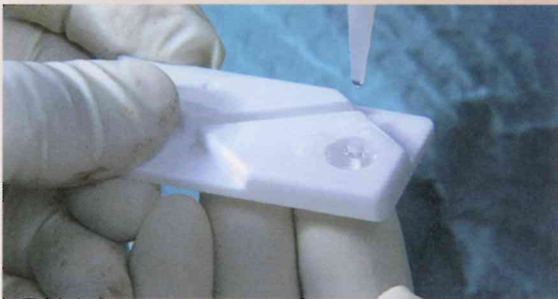
With the setting CUT 30 watt the cut is performed along the marked line with the ultra fine electrode No. 2090 ...



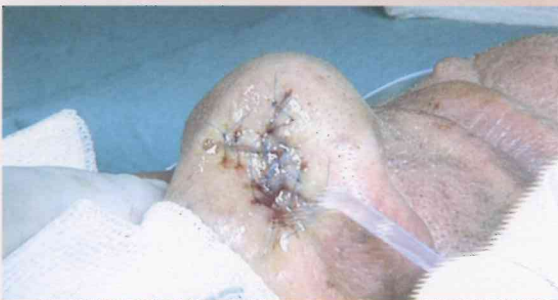... and the basalioma is prepared with pointed surgical forceps. During and after the preparation coagulation is performed via bipolar forceps.



Single button sutures are laid with Monofil 6-0 Surgipro II via 6-edge cutting needle. This needle-thread-combination is especially suitable for superior plastic-esthetical surgery.



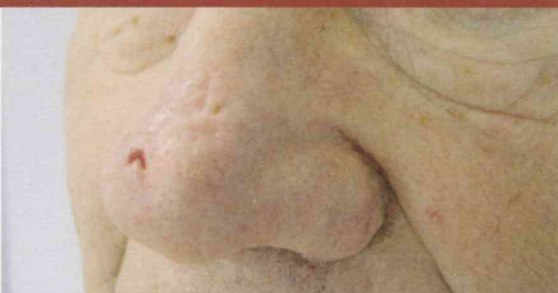After wound treatment with sutures the tissue adhesive **EPIGLU®** is applied additionally to the wound. This provides more safety for this Marcumar patient.



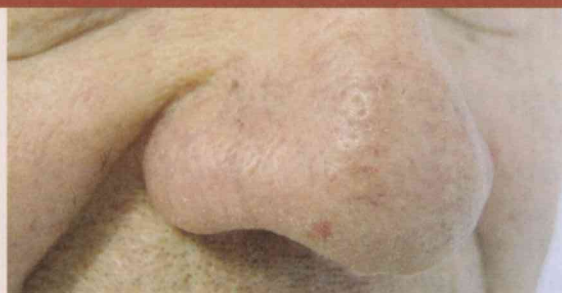The adhesive is dropped into a sterile palette, soaked up with a sterile pipette, applied to the sutured area and smoothed out.

Together with the sutures the adhesive will be removed after 6 – 8 days.

Status Postoperative



3 weeks postoperative



4 weeks postoperative

3. Removal of Xanthelasma, Hemangioma and Hair Growth perimammillary

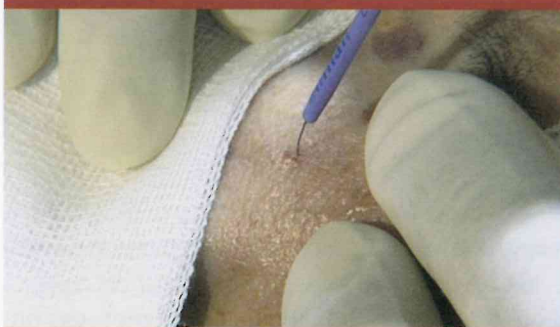Case Report

A 51 year old female patient felt very bothered by a xanthelasma and a hemangioma and wanted to use the surgical opportunity to get perimammillary hairs removed as well. The patient asked for a total intravenous anaesthesia.

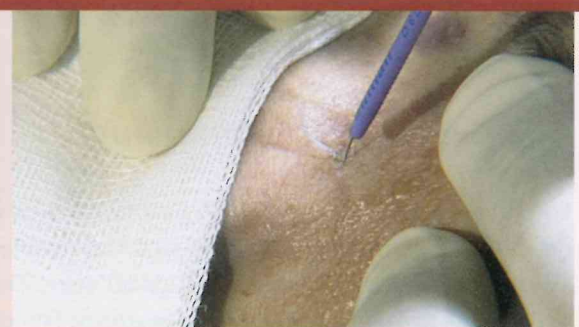The Surgical Procedures

Hemangioma

The hemangioma was coagulated with MONO COAG 9 Watt, coagulation degree c4 and a fine isolated needle electrode.



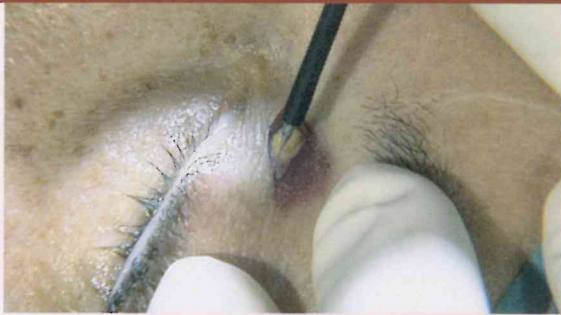
With 1–3 punctures, depending upon the size of the hemangioma, coagulation immediately occurs.



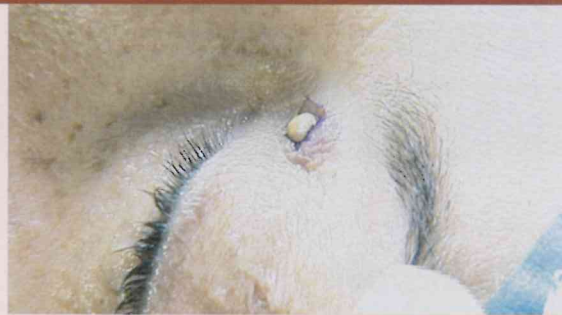Status immediately after coagulation of the hemangioma.

Xanthelasma

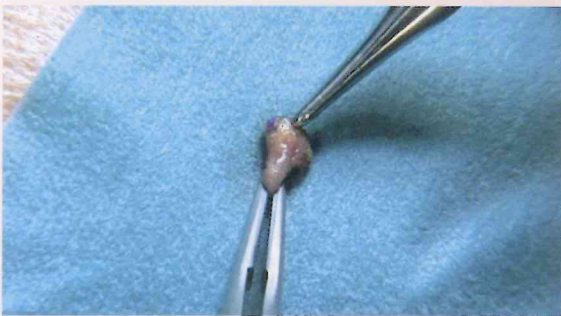
For a better presentation, the xanthelasma was injected with Xylocain 2% 1:200 000. This makes a careful removal much easier. The xanthelasma was prepared with the fine needle electrode No. 2090. With this procedure no lateral heat develops and no coagulation necroses occur. The xanthelasma can be prepared and removed completely without pressure and without any sliding of the tissue during the surgery. Of course, the histological examination can be performed up to the incision edges of the excision. Excisions will always be suitable for pathological examination if radio surgery is applied correctly. Sutures are laid with Monofil 6-0 and sharp surgical needle. After 6–8 days the threads are removed without disturbing the wound healing process.



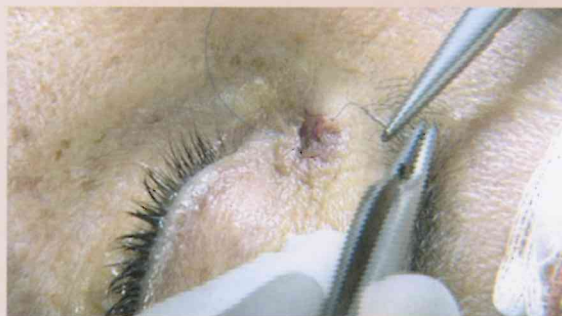With the ultra fine needle electrode No. 2090 the xanthelasma is cut along the marked line.



The dissected xanthelasma.



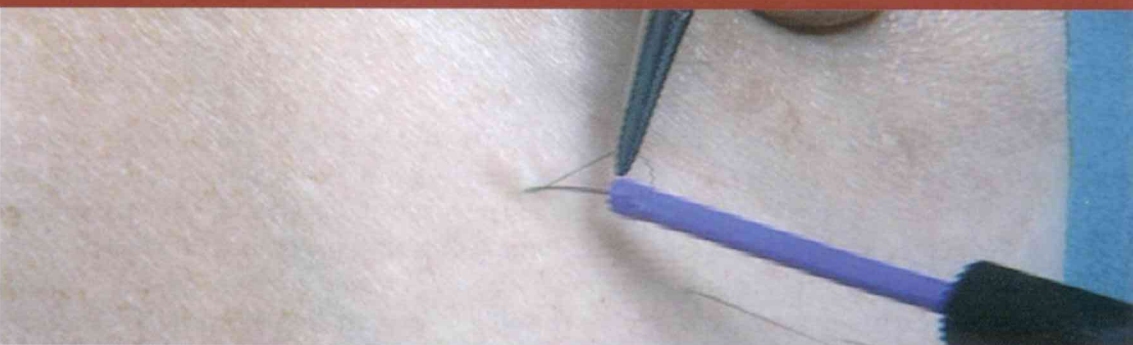
The excision can be examined up to the incision edges.



Wound closure via sutures.

Hair Growth Perimammillary

The removal of the hair growth perimammillary right, is performed with setting COAG, 9 watt, coagulation degree c4 and an isolated fine needle electrode, which is also used for epilation as well as for treatment of couperose and spider veins. The needle electrode is inserted and a short contact activated. The hair is grabbed via anatomic forceps. If it can be pulled out easily, the root was hit, destroyed and epilation was successful. If this is not the case, the procedure should be repeated. With this method the root of the hair will be destroyed so successfully that no further hair growth will occur at this place. A wound treatment is not necessary.

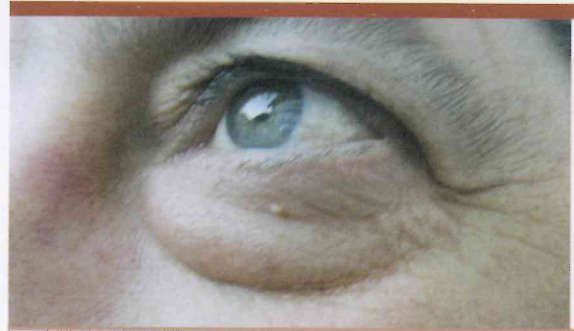

The root of the hair gets destroyed via the activated electrode and the hair extracted with forceps.

4. Traumatic Rupture of the Septum Orbitale in Ferio

Case Report

The 45 year old patient was punched in the face which resulted in a traumatic rupture of the septum orbitale. The patient felt very disturbed by the swelling of the lower eyelid, due to a restricted field of vision, which was especially troublesome when working or driving the car.



Surgical Procedure

After analgosedation with Ultiva and Propofol the surgical area was washed sterile, and a local anaesthesia with Xylocain 2% 1:200 000 was injected to the lower conjunctival sac (Fig. 1). The additional local anaestheticum swelled the conjunctival sac, which was supportive to the following surgery.

The initial cut was performed with the super fine needle electrode No. 2090, CUT/COAG 30 watt, coagulation degree c2 (Fig. 2). Along the incision lines no discolorations or other changes in the tissue were found. The septum orbitale is opened by spreading via surgical scissors. The patient is monitored by an Anaesthetist during the entire surgery (Fig. 3). The central fatty tissue hernia is presented and a partial resection is performed via scissors (Fig. 4). Coagulation is performed via bipolar forceps. After the partial removal of the medial fatty tissue hernia the reconstruction of the septum orbitale in terms of a fascial sheathing with an absorbable thread; Caprosym 4 x 0 (Fig. 5) followed.

The thermo tightening of the tissue is performed with the Colorado needle and setting MONO COAG 7 watt, coagulation degree c3. The conjunctival sac is not sealed. Due to the application of

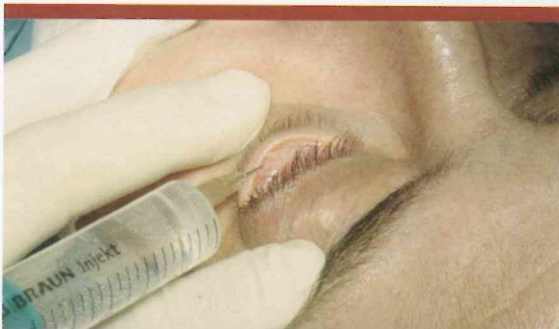


Fig. 1

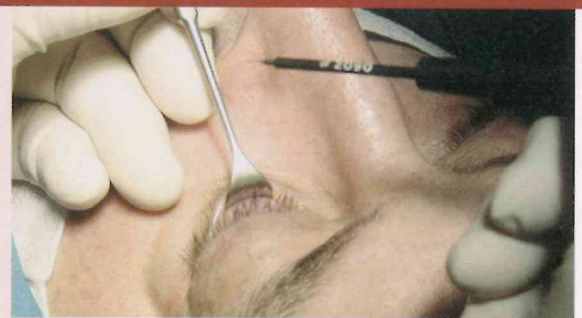


Fig. 2

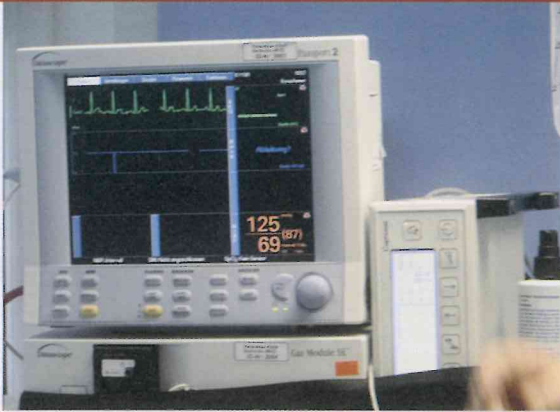


Fig. 3

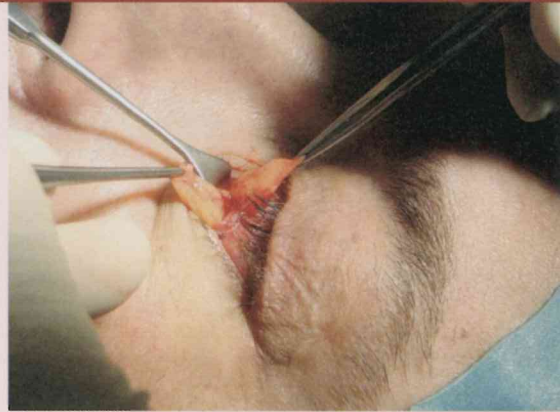


Fig. 4

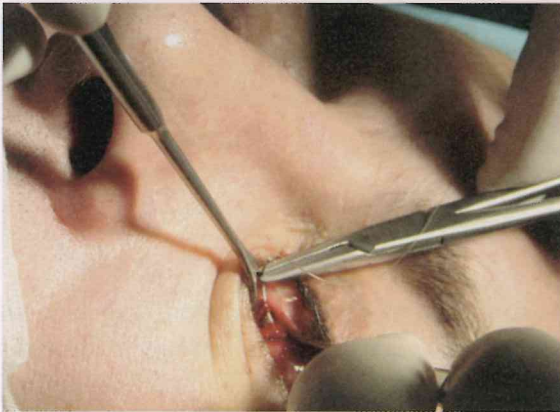


Fig. 5

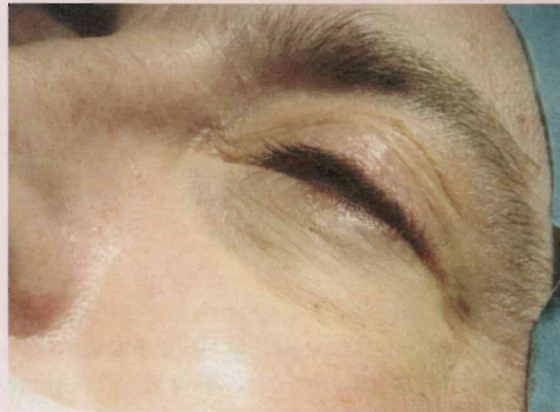

Fig. 6

radio surgery with the adjustable coagulation degree bleeding was so minimal that it could be immediately stopped during the surgery. Almost no bleeding occurred, with the result that only minor hematoma appeared. The outcome immediately postoperative is very satisfying (Fig. 6). The slight swelling will subside within the next days.

Recommendations for the Patient

The patient is instructed not to perform any straining activities especially not to lift anything heavy, not to hold the head low and not to perform any pressing exercises.

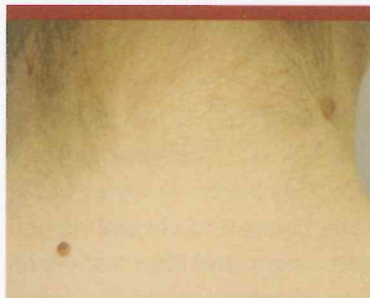
5. Removal of pigmented, papillomatous Nevus Cell Nevi at the Neck

Case Report

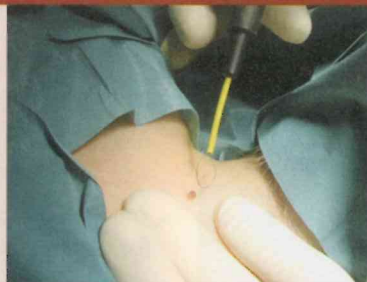
The 16 year old girl felt disturbed by 2 elevated nevi at the neck, and was concerned because both had changed recently.

Surgical Procedure

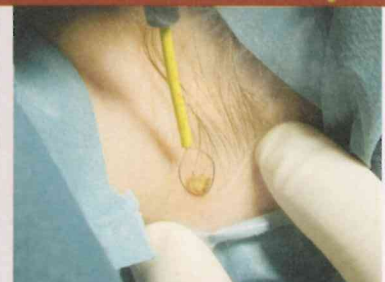After the surgical area was washed sterile, a local anaesthesia, as usual with Xylocain 2% 1:200 000, was performed. The nevi are removed with the large loop electrode No. 43 with MONO CUT/COAG 30 watt, coagulation degree c2, and the edges smoothed following. The wound treatment was solely performed with the tissue adhesive **EPIGLU®**. After the adhesive has hardened, the wound is additionally treated with a band-aid to avoid any rubbing of the clothes on the fresh wound. No further wound treatment is necessary. After some days, when, due to the advanced wound healing, new skin lamellas have been formed, the adhesive detaches itself and falls off like scab. The new pigment coating will be completed within some months. The patient can immediately resume her daily personal hygiene like washing and showering as the wound is safe from infection due to the closure with the adhesive.



Preoperative



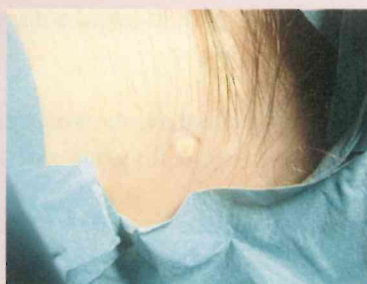Removal of the Nevi with the large loop electrode.



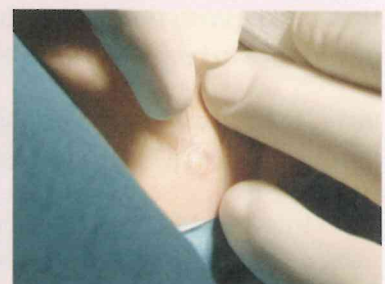The edges are smoothed.



The excisions can be examined histo-pathologically up to the incision edges.



Status immediately postoperative.

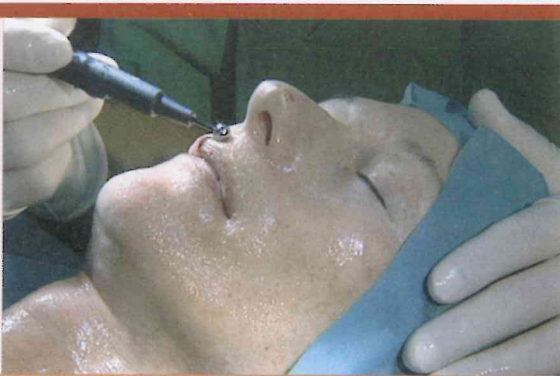
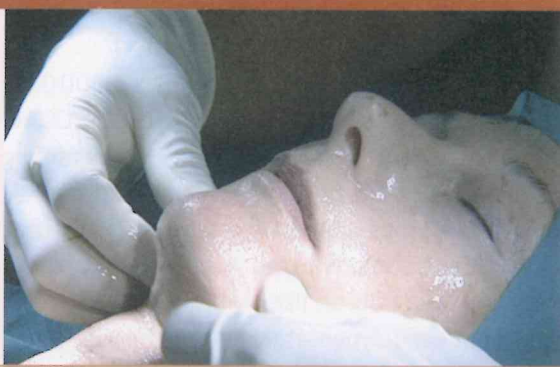
The transparent, thin layered adhesive is clearly visible.

6. Anti-Aging-Treatment with the RF-ReFacing®-Method

Case Report

The 49 year old female patient was not satisfied with her appearance and wanted to become firmer and smoother facial features without invasive surgery. The **RF-ReFacing®**-Method with radio waves was recommended.



Surgical Procedure

After cleansing, Xylocain Gel 2% is applied generously on the treatment areas and massaged gently for approx. 2 minutes. The areas around the eyes, mouth, throat and décolleté are to be treated.

With the thick ball electrode No. 08, radio waves are brought into the tissue in circling motions, without pressure. A systematic and steady action is especially important. This procedure takes about 20 – 30 minutes depending on the number and size of the areas, which are to be treated.

A slight redness at the décolleté indicates how much the skin can tolerate. The setting can be adjusted watt for watt higher or lower. In the wrinkle zones the treatment should be performed a little bit longer, and after a short recovering time the problematic zones are treated again. For the direct treatment of single wrinkles the radio waves can be applied via small ball or thick needle electrodes directly into the run of the wrinkle. With this method heat is developed. To avoid a punctual overheating it is of special importance to keep the electrode always moving.

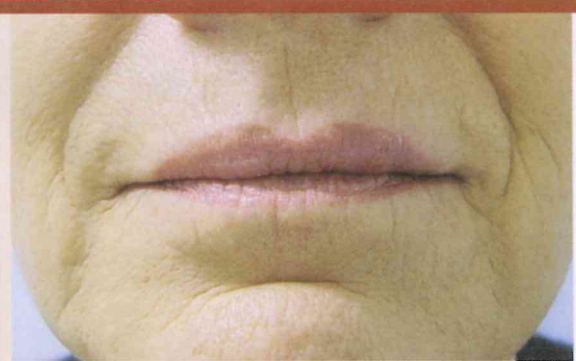
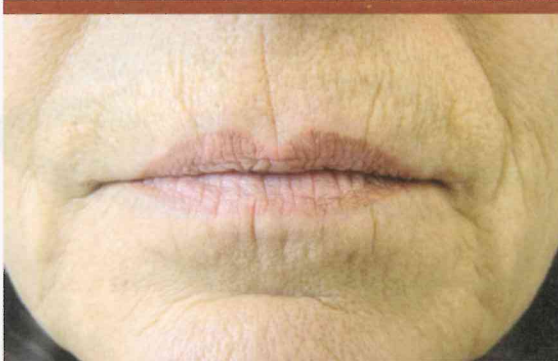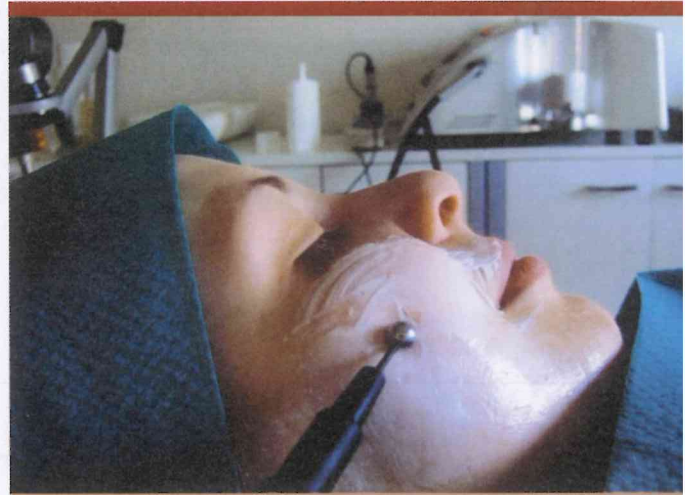
Instead of Xylocain gel or cooling gels special treatment cremes can be applied as well. The operating physician of this case has achieved good results for years with his method.

A pre-treatment for 2 – 3 weeks with suitable cremes and the application of a moisture or enzyme mask directly before the treatment with radio waves is beneficial.

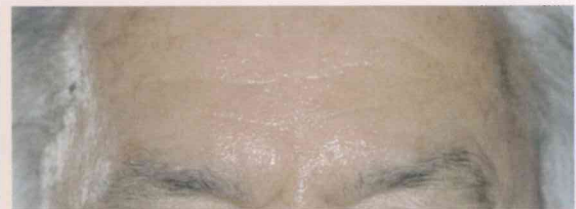The patients will observe a local reaction at the same day and further changes after 2 – 3 weeks which will increase the next 3 – 6 months, depending on the skin type. The treatment can be repeated after 2 – 6 weeks for approximately 2 – 3 times. Also later repetitions are possible without problems.

The post-treatment should be performed for approximately 3 – 4 weeks with high-quality cremes, especially developed for this purpose.

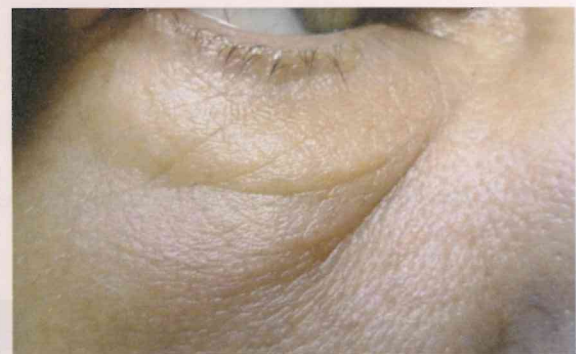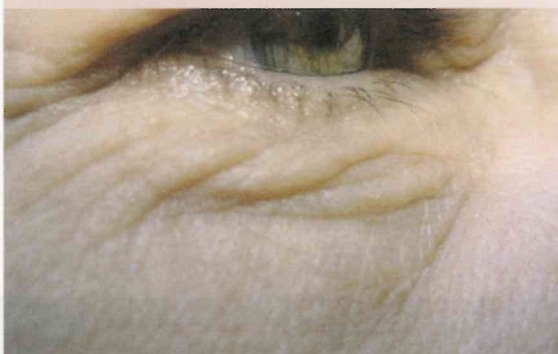With this method the facial features are tightened and wrinkles are moderated. Small crinkling wrinkles, for example at the décolleté, vanish in most cases completely. After the treatment, the patient has no displeasing, noticeable marks and the lifting takes place bit by bit in the following weeks, so nobody would assume interference. As the patient can immediately resume his social engagements, no costs for long stays at hospital or hotel will occur.



This patient wanted a treatment of the perioral wrinkles only and was very satisfied with the result.



The RF-ReFACING®-Method is also suitable for men – of course.



These perioculal wrinkles were extremely diminished after one treatment only.

The above presented cases attest that it is possible to perform a variety of surgical procedures with a radio surgical unit. In these cases the multifunctional **radioSURG® 2200**, manufactured in Germany, was used. Both in the case of incision, preparation and hemostasis the outstanding qualities come into effect. It is possible to follow every necessary anatomical or surgical line, as the cutting occurs without pressure or tension. In plastic surgery it is especially convenient that due to minor bleeding almost no hematoma occurs, therefore, the patients are almost immediately social presentable.

radioSURG® 2200 –

a universal unit for all surgical procedures, for the **RF-ReFacing®** treatment, for snoring treatment and all other surgical procedures.

